JACC: CARDIOVASCULAR IMAGING
VOL. 13, NO. 6, 2020
© 2020 BY THE AMERICAN COLLEGE OF CARDIOLOGY FOUNDATION
PUBLISHED BY ELSEVIER

MINI-FOCUS ISSUE: CARDIAC AMYLOIDOSIS

ORIGINAL RESEARCH

Low Sensitivity of Bone Scintigraphy in Detecting Phe64Leu Mutation-Related Transthyretin Cardiac Amyloidosis

Maria Beatrice Musumeci, MD,[a,*] Francesco Cappelli, MD,[b,*] Domitilla Russo, MD,[a] Giacomo Tini, MD,[c] Marco Canepa, MD, PHD,[c] Agnese Milandri, MD,[d] Rachele Bonfiglioli, MD,[e] Gianluca Di Bella, MD, PHD,[f] Filomena My, MD,[g] Marco Luigetti, MD,[h,i] Marina Grandis, MD,[j,k] Camillo Autore, MD,[a] Stefano Perlini, MD,[l] Federico Perfetto, MD, PHD,[b] Claudio Rapezzi, MD[d]

ABSTRACT

OBJECTIVES The aim of this study was to assess the diagnostic accuracy of bone scintigraphy in a large multicenter cohort of patients with cardiac amyloidotic involvement and Phe64Leu transthyretin (TTR) mutation.

BACKGROUND Diagnostic accuracy of bone scintigraphy for transthyretin-related cardiac amyloidosis (TTR-CA) is considered extremely high, enabling this technique to be the noninvasive diagnostic standard for TTR-CA. Nevertheless, this approach has not been systematically validated across the entire spectrum of TTR mutations.

METHODS A total of 55 patients with Phe64Leu TTR mutation were retrospectively analyzed and evaluated between 1993 and 2018 at 7 specialized Italian tertiary centers. Cardiac involvement was defined as presence of an end-diastolic interventricular septum thickness ≥12 mm, without other possible causes of left ventricular hypertrophy (i.e., arterial hypertension or valvulopathies). A technetium-99m (99mTc)-diphosphonate (DPD) or 99mTc-hydroxyl-methylene-diphosphonate (HMDP) bone scintigraphy was reviewed, and visual scoring was evaluated according to Perugini's method.

RESULTS Among 26 patients with definite cardiac involvement, 19 underwent 99mTc-DPD or 99mTc-HMDP bone scintigraphy. Of them, 17 (89.5%) patients had low or absent myocardial bone tracer uptake, whereas only 2 (10.5%) showed high-grade myocardial uptake. The sensitivity and the accuracy of bone scintigraphy in detecting TTR-CA were 10.5% and 37%, respectively. Patients with cardiac involvement and low or absent bone tracer uptake were similar to those with high-grade myocardial uptake in terms of age, sex, and electrocardiographic and echocardiographic findings.

CONCLUSIONS The sensitivity of bone scintigraphy (DPD and HMDP) in detecting TTR-CA is extremely low in patients with Phe64Leu TTR mutation, suggesting the need to assess diagnostic accuracy of bone scintigraphy to identify cardiac involvement across a wider spectrum of TTR mutations. (J Am Coll Cardiol Img 2020;13:1314–21)
© 2020 by the American College of Cardiology Foundation.

From the [a]Cardiology Department, Clinical and Molecular Medicine Department, Sapienza University of Rome, Rome, Italy; [b]Tuscan Regional Amyloidosis Centre, Careggi University Hospital, Florence, Italy; [c]Cardiovascular Disease Unit, IRCCS Ospedale Policlinico San Martino, and IRCCS Italian Cardiovascular Network & Department of Internal Medicine, University of Genova, Genova, Italy; [d]Cardiology, Department of Experimental, Diagnostic and Specialty Medicine, Alma Mater University of Bologna, Bologna, Italy; [e]Nuclear Medicine, Department of Experimental, Diagnostic and Specialty Medicine, Alma Mater University of Bologna, Bologna, Italy; [f]Clinical and Experimental Department of Medicine and Pharmacology, University of Messina, Messina, Italy; [g]Division of Neurology, Vito Fazzi Hospital, Lecce, Italy; [h]Fondazione Policlinico Universitario A. Gemelli IRCCS, UOC Neurologia, Rome, Italy; [i]Università Cattolica del Sacro Cuore, Sede di Roma, Rome, Italy; [j]Department of Neurology, Rehabilitation, Ophthalmology, Genetics, Maternal and Child Health (DINOGMI), University of Genova, Genova, Italy; [k]IRCCS Ospedale Policlinico San Martino, Genova, Italy; and the [l]Emergency Medicine, Department of Internal Medicine, Amyloidosis Research and Treatment Center, Fondazione IRCCS Policlinico San Matteo, University of Pavia, Pavia, Italy. *Drs. Musumeci and Cappelli contributed equally to this study. Dr. Canepa has received personal fees from Novartis, Pfizer,

ISSN 1936-878X/$36.00
https://doi.org/10.1016/j.jcmg.2019.10.015

Transthyretin-related cardiac amyloidosis (TTR-CA) is caused by the deposition of amyloid fibrils derived from either mutant transthyretin (hTTR) or wild-type transthyretin (TTR) in myocardial extracellular space (1-4). Whereas wild-type TTR amyloidosis mainly affects the heart, hTTR amyloidosis presents a broad spectrum of phenotypes, from an exclusively neurological to a predominantly cardiac form, encompassing a wide range of intermediate expressions.

More than 120 amyloidogenic TTR gene mutations have been described (5), with varying geographic distributions and organ involvement (4).

Until recently, diagnosis of TTR-CA was challenging and required demonstration of TTR amyloid deposits within myocardium by endomyocardial biopsy. However, the progressive diffusion of technetium-99m (99mTc)-diphosphonate (DPD), 99mTc-hydroxyl-methylene-diphosphonate (HMDP), or 99mTc-pyrophosphate bone scintigraphy (6-10) as a noninvasive and nonhistological technique to diagnose TTR-CA has allowed the diagnosis of this condition without the need for histology in a substantial number of cases. The paper by Gillmore et al. (7) has played a pivotal role in this process, leading to a consistent broadening of the diagnostic horizon of the disease and increasing the number of patients potentially treatable with disease modifying drugs (11,12). Nevertheless, it should be noted that the study population generating the high documented specificity and sensitivity values does not encompass the whole spectrum of TTR pathogenic mutations, and that the proposed diagnostic flow chart has never been systematically validated in external cohorts.

In our centers in the past 2 years, we have encountered anecdotal cases of hTTR amyloidosis due to the Phe64Leu mutation who presented definite signs of amyloidotic cardiac involvement without evident myocardial uptake at bone scintigraphy. This observation led us to collect a multicenter cohort of patients with TTR-CA related to this specific mutation to investigate the diagnostic accuracy of bone scintigraphy.

METHODS

We retrospectively analyzed clinical databases dedicated to TTR amyloidosis patients evaluated between 1993 and 2018 at 7 specialized Italian tertiary centers (Bologna; Messina; Tuscan Regional Amyloid referral center AOU Careggi Florence; Lecce; Azienda Universitario Ospedaliera Sant'Andrea, Roma; Policlinico Universitario Agostino Gemelli, Roma; San Martino Policlinic Hospital, Genova) to identify all Phe64Leu gene mutation carriers. All patients were managed in accordance with the Declaration of Helsinki and signed an informed consent for the processing of personal data for scientific research purposes. Demographic data, baseline neurological and cardiological assessment, and follow-up events of these patients were collected in a centralized anonymized database. Patients' phenotype (neurological and/or cardiac involvement) was subsequently defined as follows.

NEUROLOGICAL EVALUATION. Neurological involvement was defined in presence of symptoms of

ABBREVIATIONS AND ACRONYMS

99mTc = technetium-99m

CMR = cardiac magnetic resonance

DPD = diphosphonate-1,2-propanodicarboxylic acid

hTTR = mutant transthyretin

HMDP = hydroxyl-methylene-diphosphonate

LGE = late gadolinium enhancement

TTR = transthyretin

TTR-CA = transthyretin-related cardiac amyloidosis

TABLE 1 Baseline Characteristics of the 40 Affected Patients With Phe64Leu TTR Gene Mutation

Age at diagnosis, yrs	63.4 ± 8.3
Male	31 (77.5)
Family history of aTTR	22 (55)
Follow up, yrs	10.4 (0.7-13.4)
BMI, kg/m^2	23.5 ± 3.7
eGFR, ml/min*	112 ± 43
NYHA functional class III/IV	1 (2.5)
NT-proBNP, pg/ml†	226 (12-4.100.0)
BNP, ng/ml‡	104 (20-442)
Troponin I, ng/ml§	0.01 (0.001-0.710)
Peripheral neuropathy	37 (92.5)
Autonomic involvement	26 (65)
Cardiac involvement	26 (65)
Carpal tunnel syndrome	33 (82.5)
Phenotype	
Predominantly cardiac	1 (2.5)
Predominantly neurological	14 (35)
Mixed	25 (62.5)
Follow up, yrs	8.4 ± 4.7
Death	16 (40)

Values are mean ± SD, n (%), or median (range). *Data available for 20 patients; †data available for 10 patients; ‡data available for 8 patients; §data available for 14 patients.

BMI = body mass index; NYHA = New York Heart Association.

Pfizer/Bristol-Myers Squibb, Vifor Pharma, Menarini, and Sanofi. Dr. Milandri had a consultancy agreement with Alnylam. All other authors have reported that they have no relationships relevant to the contents of this paper to disclose.

The authors attest they are in compliance with human studies committees and animal welfare regulations of the authors' institutions and Food and Drug Administration guidelines, including patient consent where appropriate. For more information, visit the *JACC: Cardiovascular Imaging* author instructions page.

Manuscript received August 29, 2019; revised manuscript received October 7, 2019, accepted October 11, 2019.

TABLE 2 Detailed Description of the 26 Patients With Cardiac Involvement

Patient #	Sex	Age at Diagnosis (yrs)	IVS (mm)	EF (%)	LAD (mm)	Endomyocardial Biopsy	Visual Perugini Score	CMR	ECG	Neurological Involvement	Follow-Up
1	M	58	16	60	46	N.A.	2	N.A.	LAH	PN, CTS	Alive
2	F	73	13	67	42	+	2	N.A.	First degree AV block, LAH, RBBB (PMK)	PN, AN	Death for cachexia secondary to polyneuropathy
3	M	67	12	43	50	+	0	N.A.	First degree AV, LAH	PN, CTS	Death for unknown causes
4	M	61	13	37	45	+	N.A	N.A.	LAH, pseudonecrosis pattern	PN, AN, CTS	Death for cachexia secondary to polyneuropathy
5	M	51	13	60	42	N.A.	N.A	N.A.	First degree AV block	PN, AN, CTS	Death for cachexia secondary to polyneuropathy
6	M	72	16	60	45	N.A.	N.A	N.A.	Normal ECG	PN, CTS	Death for cachexia secondary to polyneuropathy
7	M	65	13	66	45	N.A.	N.A	N.A.	First degree AV block, pseudonecrosis pattern	PN, AN, CTS	Death for unknown causes
8	M	64	13	68	40	N.A.	0	Subendocardial LGE	Normal ECG	PN, AN, CTS	Alive
9	M	54	13	56	34	N.A.	N.A	N.A.	Normal ECG	PN, AN, CTS	Alive
10	F	65	13	61	27	N.A.	N.A	N.A.	LAH	PN, AN, CTS	Alive
11	M	58	13	73	38	N.A.	0	No LGE	Low QRS voltages	PN, AN, CTS	Alive
12	M	55	21	60	44	N.A.	N.A	Focal LGE	LAH	PN, AN, CTS	Alive
13	M	65	21	60	43	N.A.	0	Transmural LGE	LAH, RBBB, Pseudonecrosis pattern	PN, CTS	Alive
14	M	71	16	48	43	N.A.	0	Transmural LGE	AF, RBBB, Low QRS voltages	PN, AN, CTS	Death for cachexia secondary to polyneuropathy
15	M	71	14	65	44	N.A.	1	Subendocardial LGE	First degree AV block, LBBB,	PN, CTS	Death for cachexia secondary to polyneuropathy and dysautonomia
16	F	77	14	60	45	N.A.	0	No LGE	LAH	PN, AN, CTS	Alive
17	M	64	16	51	41	N.A.	0	N.A.	First degree AV block, LBBB, Pseudonecrosis pattern	PN, AN, CTS	Alive
18	M	54	13	60	38	N.A.	0	N.A.	AF, Low QRS voltages	PN, AN, CTS	Alive
19	M	64	13	57	43	N.A.	0	N.A.	Normal ECG	PN, AN, CTS	Alive
20	M	55	14	64	44	N.A.	0	N.A.	LAH	PN, AN, CTS	Alive
21	M	60	15	60	41	N.A.	0	N.A.	LAH, RBBB	PN, AN, CTS	Alive
22	M	65	16	60	40	N.A.	1	N.A.	LAH, RBBB	PN, AN, CTS	Death for unknown causes
23	M	75	15	54	42	N.A.	0	Focal LGE	Low QRS voltages, Pseudonecrosis pattern	PN, AN	Death for generalized wasting
24	F	63	14	65	39	N.A.	1	N.A.	Normal ECG	–	Alive
25	M	60	14	67	43	N.A.	1	N.A.	Pseudonecrosis pattern	PN, AN, CTS	Sudden death
26	M	77	18	56	36	N.A.	0	Focal LGE	First degree AV block, LAH	PN, AN, CTS	Alive

AF = atrial fibrillation; AN = autonomic neuropathy; AV = atrioventricular; CMR = cardiac magnetic resonance; CTS = carpal tunnel syndrome; EF = ejection fraction; IVS = interventricular septum; LAD = left atrial dimension, LAH = left anterior hemiblock; LBBB = left bundle branch block; LVH = left ventricular hypertrophy; LGE = late gadolinium enhancement; N.A. = not available; PMK = pacemaker; PN = peripheral neuropathy; RBBB = right bundle branch block.

progressive sensorimotor or autonomic neuropathy. Neurological assessment included evaluation of symptoms indicative of motor, sensory, and autonomic dysfunction. A complete clinical examination (i.e., electromyography with nerve conduction studies and sympathetic skin response, quantitative sensation test, quantitative autonomic test) was used to detect, characterize, and scale the severity of neuropathic abnormalities involving small and large nerve fibers. Carpal tunnel syndrome history was considered positive in the presence of typical symptoms or of previous surgery for median nerve decompression.

CARDIOLOGICAL EVALUATION. Cardiac involvement was defined in presence of an end-diastolic interventricular septum thickness ≥12 mm at echocardiographic evaluation, in the absence of other causes of left ventricular hypertrophy (i.e., arterial hypertension or valvulopathies), with exclusion of monoclonal gammopathy on serum and urine samples. Cardiological assessment included New York Heart Association functional classification to define cardiac functional capacity. Electrocardiography and echocardiography evaluations were performed in all individuals. Standard definitions were used for the interpretation of 12-lead electrocardiograms (ECGs).

Low QRS voltages were defined as QRS amplitude ≤0.5 mV in all limb leads or ≤1 mV amplitude in all precordial leads. The voltage/mass ratio was defined as total QRS score divided by left ventricular mass measured on echocardiogram indexed to body surface area. Echocardiographic images were obtained from the standard parasternal long-axis, parasternal short-axis, apical, and subcostal views with commercially available vendor machines. Left ventricular ejection fraction quantification and diastolic function were evaluated according to the recommendations of the European Association of Cardiovascular Imaging (13). Left ventricular mass, diameters, and wall thickness were evaluated by M-mode according to Deveraux formula (14).

BONE SCINTIGRAPHY. Bone scintigraphy, either with 99mTc-DPD or 99mTc-HMDP, depending from each site availability, was performed according to clinical need and center availability. Two sets of images were obtained (5 min and 3 h after radiotracer injection). Only planar images were disposable. Visual scoring was evaluated according to Perugini's method (6): score 0, absent cardiac uptake and normal bone uptake; score 1, mild cardiac uptake, lower than bone uptake; score 2, moderate cardiac uptake associated with reduced bone uptake; or score 3, strong cardiac uptake with mild/absent bone uptake. Two experienced specialists in nuclear medicine independently performed the image analyses and there were no cases of disagreement.

CARDIAC MAGNETIC RESONANCE. Electrocardiographically gated cardiac magnetic resonance (CMR) was performed according to clinical need and center availability. The late gadolinium enhancement (LGE) images were acquired on average 5 min after administering gadodiamide 0.1 mmol/kg using a segmented inversion recovery gradient echo technique, constantly adjusting the inversion time to null normal myocardium. The LGE pattern was classified into 4 patterns according to the degree of transmurality as no LGE, focal, global, subendocardial, and transmural LGE (15).

GENOTYPING. Genetic testing was performed at all sites using different platforms available over time.

TTR gene analysis was carried out in all patients. Genomic DNA was isolated from whole peripheral blood by standard techniques.

STATISTICAL ANALYSIS. Data were analyzed with SPSS software version 25 (SPSS Inc., Chicago, Illinois). Continuous variables were presented as mean ± SD or median with interquartile range (25° to 75°). Sensitivity, specificity, predictive and negative value, and diagnostic accuracy of radionuclide scan findings (score ≥2) were calculated.

TABLE 3 Baseline Electrocardiographic and Echocardiographic Findings in Phe64Leu Patients With Cardiac Involvement According to Myocardial Bone Tracers Uptake

	Absent or Low Myocardial Bone Tracer Uptake (Perugini Score = 0 or 1) (N = 17)	High Grade Myocardial Bone Tracers Uptake (Perugini Score = 2)	
		Patient #1	Patient #2
Age at diagnosis, yrs	64 (60-71)	58	73
Male	15 (88.2)	M	F
NYHA functional class III/IV	0 (0)	Yes	No
Normal ECG	3 (17.6)	No	No
Atrial fibrillation	2 (11.8)	No	No
Permanent pacemaker	0 (0)	No	Yes
First-degree AV block	4 (23.5)	No	Yes
Low QRS voltages	4 (23.5)	No	No
Voltage/mass, mV/g/m^2 BSA	0.96 (0.65-1.10)	0.74	1.3
Right bundle branch block	4 (23.5)	No	Yes
Left bundle branch block	2 (11.7)	No	No
Left anterior hemiblock	7 (41.1)	Yes	Yes
Pseudonecrosis pattern	4 (23.5)	No	No
Diastolic IVS, mm	14 (13-16)	16	13
Diastolic LV PW, mm	12 (11-13)	16	13
Left atrial diameter, mm	42 (40-43)	46	42
LVEF, %	60 (56-65)	60	67
LVEDD, mm	46 (42-49)	43	42
LVESD, mm	29 (26-33)	29	25
Grade II to III diastolic dysfunction	8 (47)	Yes	No
Pericardial effusion	2 (11.8)	Yes	No
LV mass, g/m^2 BSA	207.4 (199.3-240.2)	134.4	121.5
Perugini grade 0	13 (76.5)		
Perugini grade 1	4 (23.5)		
Perugini grade 2	0 (0)	1	1
Perugini grade 3	0 (0)		
CMR	8 (47)	N.A.	N.A.
Presence of LGE			
No	2 (25)		
Patchy	2 (25)		
Subendocardial	2 (25)		
Transmural	2 (25)		

Values are median (interquartile range) or n (%).

AV = atrioventricular; BSA = body surface area; CMR = cardiac magnetic resonance; ECG = electrocardiogram; EF = ejection fraction; IVS = interventricular septum; LGE = late gadolinium enhancement; LV = left ventricular; LVEDD = left ventricular end-diastolic diameter; LVEF = left ventricular ejection fraction; LVESD = left ventricular end-systolic diameter; N.A = not available; PW = posterior wall.

RESULTS

A total of 55 consecutive Italian Caucasian subjects carrying the Phe64Leu TTR gene mutation were identified, of whom 15 were unaffected carriers. Baseline characteristics and follow-up data of the 40 affected patients (mean age at diagnosis 63.4 ± 8.3 years; 77.5% men) are shown in Table 1. Cardiac involvement was found in 26 patients (Table 2). The

CENTRAL ILLUSTRATION Relation Between End-Diastolic Interventricular Septum Thickness and Visual Perugini Grading Score at Bone Scintigraphy

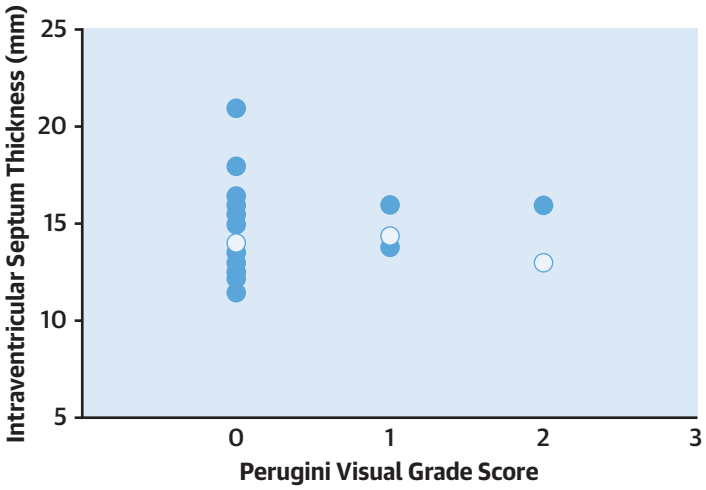

Musumeci, M.B. et al. J Am Coll Cardiol Img. 2020;13(6):1314–21.

Scatter graph showing the relation between end-diastolic interventricular septum thickness and visual Perugini grading score at 99mTc-DPD or 99mTc-HMDP bone scintigraphy. **Blue circles** represent men and **white circles** represent women. 99mTc = technetium-99m; DPD = diphosphonate-1,2-propanodicarboxylic acid; HMDP = hydroxyl-methylene-diphosphonate.

majority of these patients generally had no symptoms or were mildly symptomatic for dyspnea at baseline evaluation, with the exception of 1 patient who was in New York Heart Association functional class III. Myocardial biomarkers were available only for few of them and resulted mildly increased.

BONE TRACER UPTAKE AND CARDIAC INVOLVEMENT. Among the 26 patients with cardiac involvement, 19 underwent 99mTc-DPD or -HMDP bone scintigraphy. Of them, 17 (89.5%) patients had low or absent myocardial bone tracer uptake (13 with Perugini score = 0 and 4 with Perugini score = 1) whereas only 2 (10.5%) patients had high-grade myocardial bone tracer uptake (Perugini score = 2). A total of 8 patients without cardiac involvement underwent 99mTc-DPD or -HMDP bone scintigraphy that resulted negative (Perugini score = 0) in all cases. Considering only the high-grade bone tracer uptake (Perugini ≥2), the sensitivity of 99mTc-DPD or -HMDP bone scintigraphy in detecting cardiac involvement was 10.5% (95% confidence interval [CI]: 1.3% to 33.1%), the negative predictive value was 32% (95% CI: 28.7% to 35.4%), and the diagnostic accuracy was 37% (95% CI: 19.4% to 57.6%). Including any degree of bone tracer uptake, the sensitivity of 99mTc-DPD or -HMDP bone scintigraphy in detecting cardiac involvement would increase to 31.5% (95% CI: 12.58% to 56.55%) and the diagnostic accuracy to 50.9% (95% CI: 31.9% to 71.3%).

Patients with cardiac involvement and low or absent myocardial bone tracer uptake did not differ from those with high-grade myocardial bone tracer uptake in regard of clinical, electrocardiographic, and echocardiographic characteristics (Table 3). The Central Illustration shows the relation between end-diastolic interventricular septum thickness and visual Perugini grading score at 99mTc-DPD or -HMDP bone scintigraphy. A total of 5 patients with interventricular septum thickness ≥15 mm had visual grade Perugini score = 0.

A total of 8 patients with cardiac involvement but low or absent 99mTc-DPD or -HMDP bone scintigraphy underwent CMR. In 6 (75%) cases, this examination showed the presence of LGE: 2 patients with focal LGE, 2 patients with subendocardial LGE, and 2 patients with transmural LGE.

Endomyocardial biopsy was performed in 3 patients with cardiac involvement, and all demonstrated the deposition of TTR amyloid fibrils. Two of them also underwent 99mTc-DPD bone scintigraphy, which in 1 case showed a high-grade myocardial bone tracer uptake (Perugini score = 2), whereas in the other resulted negative (Perugini score = 0).

Figure 1 reports an example of a Phe64Leu TTR patient and cardiac involvement, with typical ECG and echocardiographic findings suggesting cardiac amyloidosis, diffuse subendocardial LGE on CMR, but without 99mTc-HMDP myocardial uptake at bone scintigraphy (Perugini score = 0).

DISCUSSION

In this sizeable cohort of TTR Phe64Leu patients, we found a very low sensitivity (10.5%) of bone scintigraphy in detecting CA leading to a 37% diagnostic accuracy.

After the publication of the paper by Gillmore et al. (7), the use of bone scintigraphy as a noninvasive tool for CA diagnosis has progressively expanded with a significant impact on clinical practice. The excellent values of sensitivity (>99%) and specificity (86%) of bone scintigraphy derived from the analysis of 857 patients with histologically proven amyloidosis, of whom 258 were affected by hTTR and carriers of 35 different TTR gene mutations (7). Therefore, not all the TTR gene mutations known to be causative of a cardiac phenotype were included and specifically analyzed. Particularly, only 2 hTTR Phe64Leu patients were included in the study: of note, despite proven cardiac involvement, both showed low-grade

FIGURE 1 Representative Case of a Phe64Leu TTR Patient With Cardiac Involvement and Negative Bone Scintigraphy

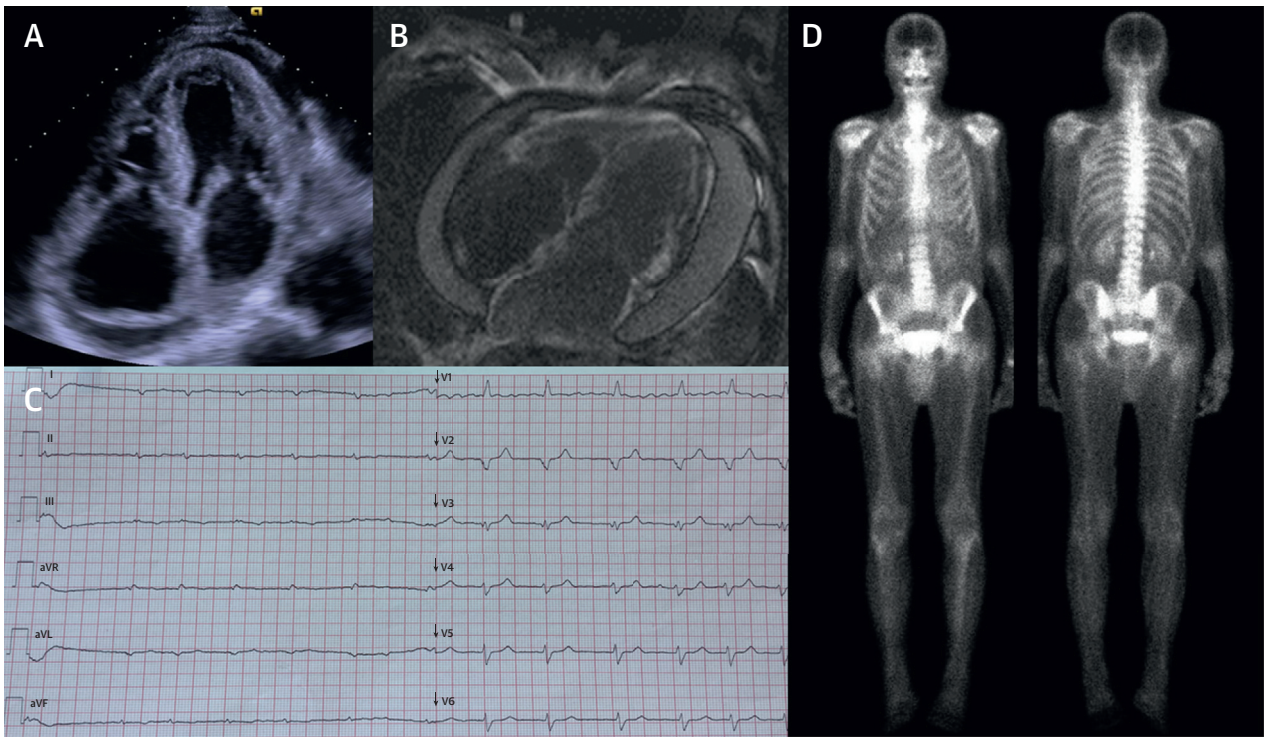

(A) Echocardiography showed symmetric left ventricular hypertrophy, severe biatrial dilatation, and circumferential pericardial effusion. **(B)** Cardiac magnetic resonance showed diffuse LGE. **(C)** Electrocardiogram demonstrated atrial fibrillation and diffuse low voltages. **(D)** Tc99-HMDP bone scintigraphy did not show myocardial bone tracer uptake.

scintigraphy uptake (Perugini score 1). Nevertheless, the workup proposed, although never externally validated, has been widely and unanimously accepted (16,17). Indeed, TTR-CA as proven by bone scintigraphy is nowadays an acceptable criterion both for enrollment patients in clinical trials investigating disease-modifying drugs and for registration of novel agents at drug regulatory agencies (12,16,18).

Our findings for the first time demonstrated an unexpected low sensitivity of bone scintigraphy in a sizeable cohort of Caucasian patients with Phe64Leu TTR mutation. Even if only 2 patients underwent endomyocardial biopsy (confirming the diagnosis of TTR-CA), in all cases, clinical, electrocardiographic, echocardiographic, and CMR data, in the presence of a known causative TTR mutation, made the diagnosis of TTR-CA extremely likely. In particular, 5 patients with interventricular septum thickness ≥15 mm had visual grade Perugini score = 0. Moreover, CMR was able to detect an LGE pattern highly suggestive of cardiac infiltration in almost 75% of Phe64Leu TTR patients with negative bone scintigraphy.

A clear explanation for this lack of sensitivity of bone scintigraphy in patients with Phe64Leu mutation cannot be provided by our study. More in general, the intimate mechanisms of bone tracers binding to myocardium in TTR-CA remains unknown, although different determinants have been suggested (19). First, the uptake of phosphonates in amyloidotic tissues might be explained by high calcium content in amyloid deposits (19-22). Moreover, it has been hypothesized that the myocardial affinity of bone tracers may be related to the amyloid fibril composition (19). Indeed, amyloid fibrils may contain 2 different components: a mixture of C-terminal fragments and full-length TTR (type A), and a full-length TTR (type B). The type of fibrils (A or B) generating the amyloid deposits are the result of complex and unknown genetic or environmental factors (23-25).

FIGURE 2 Diagnostic Flow Chart in Patients With Suspected Cardiac Involvement and Phe64Leu Mutation

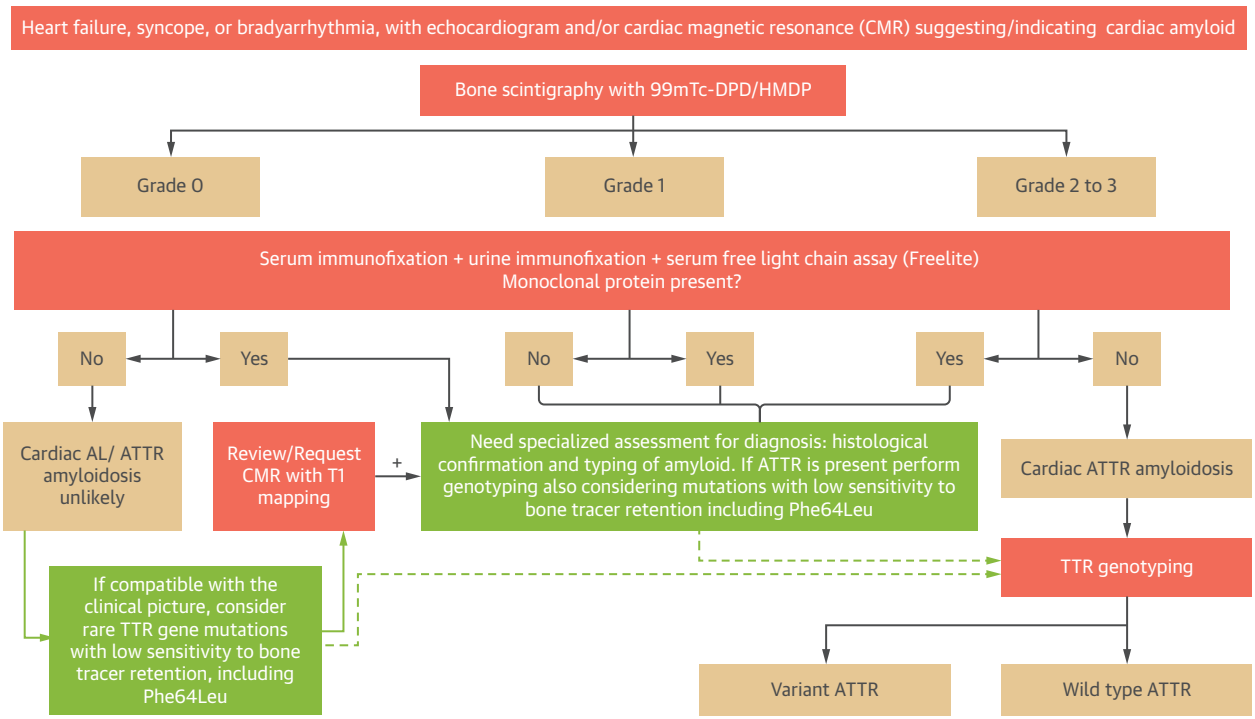

The suggested flow chart was adapted by the referral one proposed by Gilmore et al. (7). Echocardiographic features suggesting/indicating cardiac amyloid include left ventricular wall thickness >12 mm in the absence of other causes of left ventricular hypertrophy. CMR should be considered positive in presence of restrictive morphology, abnormal gadolinium kinetics, and extracellular volume expansion based on T_1 mapping. 99mTc = technetium-99m; CMR = cardiac magnetic resonance; DPD = diphosphonate-1,2-propanodicarboxylic acid; HMDP = hydroxyl-methylene-diphosphonate.

In a recent study, approximately the total of patients with type A amyloid fibrils had significant 99mTc-DPD uptake at scintigraphy, whereas none of the patients with type B fibrils displayed detectable radiotracer heart retention (26). Notably, type B fibrils have been found in a restricted number of patients with TTR mutations, including Phe64Leu (27). Furthermore, no evidence of relationships between the degree of myocardial 99mTc-DPD uptake as assessed by visual Perugini score and left ventricular mass and/or interventricular septal thickness emerged (6).

STUDY LIMITATIONS. We acknowledge that the limited number of cardiac biopsies in patients with negative 99mTc-DPD or -HMDP bone scintigraphies not allow to consider definite our results. Nevertheless, our research clearly suggests that in a large cohort of Phe64Leu ATTR patients, despite clearly and concordant ECG, echocardiographic, and CMR signs of cardiac amyloid involvement, few or absent bone tracer cardiac uptake has been evidenced.

CONCLUSIONS

Our study advises the urgent need to assess diagnostic accuracy of bone scintigraphy across a wider spectrum of TTR mutations in different geographic area. Moreover, as proposed in **Figure 2**, in the presence of high suspicion of cardiac involvement in hTTR patients, a negative bone scintigraphy could not completely rule out an amyloid cardiomyopathy and a multimodal approach comprising CMR and cardiac biopsy should be considered to avoid a failure in diagnosis.

ADDRESS FOR CORRESPONDENCE: Dr. Francesco Cappelli, Tuscan Regional Amyloidosis Centre, Careggi University Hospital, Heart Lung and Vessels, Largo Brambilla 3, Florence 50134, Italy. E-mail: cappellif@aou-careggi.toscana.it.

PERSPECTIVES

COMPETENCY IN MEDICAL KNOWLEDGE: In a large cohort of patients with the specific Phe64Leu TTR mutation, sensitivity of bone scintigraphy in detecting cardiac involvement appears extremely low, and in presence of high suspicion of cardiac involvement, a multimodal approach comprising CMR and cardiac biopsy should be considered to avoid a failure in diagnosis.

TRANSLATIONAL OUTLOOK: Additional studies are needed to assess the diagnostic accuracy of bone scintigraphy in a wider spectrum of TTR mutations, also considering the diffusion of disease-modifying drugs for TTR amyloidosis and the increasing number of potentially treatable patients, if correctly identified.

REFERENCES

1. Rapezzi C, Quarta CC, Riva L, et al. Transthyretin-related amyloidoses and the heart: a clinical overview. Nat Rev Cardiol 2010;7:398–408.

2. Plante-Bordeneuve V, Said G. Familial amyloid polyneuropathy. Lancet Neurol 2011;10:1086–97.

3. Merlini G, Bellotti V. Molecular mechanisms of amyloidosis. N Engl J Med 2003;349:583–96.

4. Sperry BW, Tang WH. Amyloid heart disease: genetics translated into disease-modifying therapy. Heart 2017;103:812–7.

5. Rowczenio DM, Noor I, Gillmore JD, et al. Online registry for mutations in hereditary amyloidosis including nomenclature recommendations. Hum Mutat 2014;35:E2403–12.

6. Perugini E, Guidalotti PL, Salvi F, et al. Noninvasive etiologic diagnosis of cardiac amyloidosis using 99mTc-3,3-diphosphono-1,2-propanodicarboxylic acid scintigraphy. J Am Coll Cardiol 2005;46:1076–84.

7. Gillmore JD, Maurer MS, Falk RH, et al. Nonbiopsy diagnosis of cardiac transthyretin amyloidosis. Circulation 2016;133:2404–12.

8. Cappelli F, Gallini C, Di Mario C, et al. Accuracy of 99mTc-hydroxymethylene diphosphonate scintigraphy for diagnosis of transthyretin cardiac amyloidosis. J Nucl Cardiol 2019;26:497–504.

9. Papantoniou V, Valsamaki P, Kastritis S, et al. Imaging of cardiac amyloidosis by (99m)Tc-PYP scintigraphy. Hell J Nucl Med 2015;18:42–50.

10. Bokhari S, Castaño A, Pozniakoff T, Deslisle S, Latif F, Maurer MS. (99m)Tc-pyrophosphate scintigraphy for differentiating light-chain cardiac amyloidosis from the transthyretin-related familial and senile cardiac amyloidoses. Circ Cardiovasc Imaging 2013;6:195–201.

11. Emdin M, Aimo A, Rapezzi C, et al. Treatment of cardiac transthyretin amyloidosis: an update. Eur Heart J 2019 [E-pub ahead of print].

12. Maurer MS, Schwartz JH, Gundapaneni B, et al. Tafamidis treatment for patients with transthyretin amyloid cardiomyopathy. N Engl J Med 2018;379:1007–16.

13. Lang RM, Badano RP, Mor-Avi V, et al. Recommendations for cardiac chamber quantification by echocardiography in adults: an update from the American Society of Echocardiography and the European Association of Cardiovascular Imaging. Eur Heart J Cardiovasc Imag 2015;16:233–70.

14. Deveraux RB, Alonso DR, Lutas EM, Gottlieb GJ, Campo E, Sachs I, Reichek N. Echocardiographic assessment of left ventricular hypertrophy: comparison to necropsy findings. Am J Cardiol 1986;57:450–8.

15. Fontana M, Pica S, Reant P, et al. Prognostic value of late gadolinium enhancement cardiovascular magnetic resonance in cardiac amyloidosis. Circulation 2015;132:1570–9.

16. Ruberg FL, Grogan M, Hanna M, Kelly JW, Maurer MS. Transthyretin amyloid cardiomyopathy: JACC state-of-the-art review. J Am Coll Cardiol 2019;73:2872–91.

17. Witteles RM, Bokhari S, Damy T, et al. Screening for transthyretin amyloid cardiomyopathy in everyday practice. J Am Coll Cardiol Heart Fail 2019;7:709–16.

18. Judge DP, Heitner SB, Falk RH, et al. Transthyretin stabilization by AG10 in symptomatic transthyretin amyloid cardiomyopathy. J Am Coll Cardiol 2019;74:285–95.

19. Rapezzi C, Gagliardi C, Milandri A. Analogies and disparities among scintigraphic bone tracers in the diagnosis of cardiac and noncardiac ATTR amyloidosis. J Nucl Cardiol 2019;26:1638–41.

20. Falk RH, Lee VW, Rubinow A, Hood WB Jr., Cohen AS. Sensitivity of technetium-99m-pyrophosphate scintigraphy in diagnosing cardiac amyloidosis. Am J Cardiol 1983;51:826–30.

21. Willerson JT, Parkey RW, Bowe TJ, Lewis SE, Corbett J, Buja LM. Pathophysiologic considerations and clinical-pathological correlates of technetium-99m stannous pyrophosphate myocardial scintigraphy. Semin Nucl Med 1980;10:54–69.

22. Yood RA, Skinner M, Cohen AS, Lee VW. Soft tissue uptake of bone seeking radionuclide in amyloidosis. J Rheumatol 1981;8:760–6.

23. Oshima T, Kawahara S, Ueda M, et al. Changes in pathological and biochemical findings of systemic tissue sites in familial amyloid polyneuropathy more than 10 years after liver transplantation. J Neurol Neurosurg Psychiatry 2014;85:740–6.

24. Pepys MB, Dyck RF, de Beer FC, Skinner M, Cohen AS. Binding of serum amyloid P-component (SAP) by amyloid fibrils. Clin Exp Immunol 1979;38:284–93.

25. Ihse E, Rapezzi C, Merlini G, et al. Amyloid fibrils containing fragmented ATTR may be the standard fibril composition in ATTR amyloidosis. Amyloid 2013;20:142–50.

26. Pilebro B, Suhr OB, Näslund U, Westermark P, Lindgvist P, Sundstrom T. (99m)Tc-DPD uptake reflects amyloid fibril composition in hereditary transthyretin amyloidosis. Ups J Med Sci 2016;121:17–24.

27. Suhr OB, Wixner J, Anan I, Lundgren HE, Wijayatunga P, Westermark P, Ihse E. Amyloid fibril composition within hereditary Val30Met (p. Val50Met) transthyretin amyloidosis families. Plos ONE 2019;14:e0211983.

KEY WORDS bone scintigraphy, cardiac amyloidosis, Phe64Leu mutation