European Heart Journal Supplements (2020) **22** (Supplement E), E142–E147
The Heart of the Matter
doi:10.1093/eurheartj/suaa080

ESC
European Society
of Cardiology

Cardiac amyloidosis: do not forget to look for it

Aldostefano Porcari[1], Luca Falco[1], Veronica Lio[2], Marco Merlo[1], Enrico Fabris[1], Rossana Bussani[3], and Gianfranco Sinagra[1]*

[1]*Cardiovascular Department, Azienda Sanitaria Universitaria Integrata, University of Trieste (ASUITS), Trieste, Italy;* [2]*Division of Clinical Cardiology, Azienda Ospedaliera Universitaria 'Maggiore della Carità', Novara, Italy; and* [3]*Pathology Department, Azienda Sanitaria Universitaria Integrata, University of Trieste (ASUITS), Trieste, Italy*

KEYWORDS
Cardiac amyloidosis;
Diagnosis;
Epidemiology;
Myocardial scintiscan;
Heart failure

Amyloidosis is a systemic disease due to buildup of protein material in the extracellular space, which can affect the heart, mainly in its light chain and transtyretin forms. Historically this condition has been considered very uncommon, and it was certainly under-diagnosed. Today is well known that in certain group of patients its prevalence is, indeed, very high (25% in patients over the age of 80 years; 32% in patients over 75 years with heart failure and preserved systolic function, and 5% in post-mortem series of hypertrophic cardiomyopathy). Some genetically determined form of transthyretin amyloidosis are quite common in certain populations, such as Caribbean origin African-Americans. The wide spectrum of signs, symptoms, and first-level tests often overlapping among various other conditions, represent a diagnostic challenge for the clinical cardiologist. The opportunity to reach the diagnosis with non-invasive testing (first and foremost scintiscan with bone markers), as well as encouraging results of newer classes of drugs, raised the interest in this condition, so far burdened by an ominous prognosis. Early diagnosis of amyloidosis should always be guided by clinical suspicion but should also be supported by a multidisciplinary approach, aimed at optimizing the prognosis of the condition. Despite the newer drugs now available, a late diagnosis affect negatively the prognosis, and the opportunity to implement *disease-modifying* therapies (e.g. liver transplant in ATTR, or bone marrow transplant in AL) able to cure or at least delay the progression of the disease.

Introduction

Amyloidosis is an infiltrative systemic disease characterized by pathological accumulation in the extracellular site of insoluble fibrils (*Figure 1*), resistant to proteolysis, derived from the altered folding of some proteins (more than 30 are known).[1] Cardiac involvement (termed cardiac amyloidosis—CA) is the most significant prognostic event in the natural history of the disease and is also the main cause of death, most frequently secondary to insufficient (bi) ventricular pump. The main protein precursors responsible for CA are the light chains of immunoglobulins (AL or primary form) and the transthyretin, both 'mutated' (TTRm or familial form) and 'wild type' (TTRwt). The different pathogenicity of the precursors is reflected in the gap between the average survival rates from the onset of heart failure in untreated patients: between 6 and 12 months in the AL and between 24 and 42 months in the TTR.[2]

AC is one of the most critical diagnostic challenges for the modern clinical cardiologist. The fragmentation of knowledge between specialists in different clinical fields associated with the great phenotypic heterogeneity of the disease requires specific competence and a high level of suspicion to formulate a correct and timely diagnosis. The widespread belief of CA as a rare and incurable disease is denied by the most recent scientific evidences that depict an epidemiology that is profoundly different from the past and in evolution, especially after the introduction of

*Corresponding author. Email: gianfranco.sinagra@asuits.sanita.fvg.it

Published on behalf of the European Society of Cardiology. © The Author(s) 2020.
This is an Open Access article distributed under the terms of the Creative Commons Attribution Non-Commercial License (http://creativecommons.org/licenses/by-nc/4.0/), which permits non-commercial re-use, distribution, and reproduction in any medium, provided the original work is properly cited. For commercial re-use, please contact journals.permissions@oup.com

Downloaded from https://academic.oup.com/eurheartjsupp/article/22/Supplement_E/E142/5851037 by guest on 26 August 2021

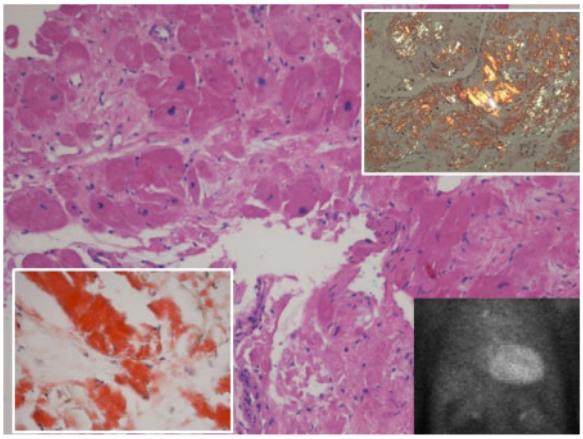

Figure 1 Typical histological aspect of myocardium with amyloidotic infiltrates: on the background, haematoxylin-eosin staining, on the upper right, yellow-green birefringence in polarized light, lower left in Congo red colour. Pathological Anatomy Archive, University of Trieste, courtesy of Prof. Bussani. In the lower right pane, myocardial hypercapacitation of the bone tracer at scintigraphy of a patient with amyloidotic cardiomyopathy from wild-type transthyretin.

diagnostic methods of nuclear medicine. The development of new drugs capable of acting at the molecular and genetic level is significantly changing therapeutic strategies and the prognosis of a disease with high mortality, especially in the presence of cardiac involvement. These novelties in the diagnostic and therapeutic field have recently sparked a keen interest in this condition.

The poor prognosis identifies in the early diagnosis the key element for a timely start of specific therapies able to slow down the progression or, where possible, modify the natural history of the pathology. At the state-of-the-art, this remains a largely neglected critical point, since the average time from clinical onset to diagnosis is two years in the AL form. Similar data emerges for the ATTR, generally diagnosed within six months in less than half of the affect's patients.[3]

The epidemiological metamorphosis of cardiac amyloidosis

The international scientific community is experiencing a phase of extreme dynamism and evolution in the epidemiological field of CA, especially in light of the new diagnostic strategies offered by non-invasive methods, such as myocardial scintigraphy. The possibility of reaching the diagnosis of CA in the TTR form through nuclear imaging methods in some well-selected patients, without therefore needing histological confirmation, constitutes a great revolution in the clinical-assistance field and is helping to rewrite the epidemiology of a disease by long time forgotten. The AL form has so far been considered the first cause of CA, with a prevalence of 8–12 cases per million people, but more and more reports of the current literature underline a widespread and alarming underestimate of the ATTR form. In large case studies of autopsy, the presence of intramyocardial TTR deposits has been documented in more than 25% of subjects over 80 and in about 32% of patients with heart failure with preserved ejection fraction aged >75 years (vs. 8% of age < 75 years).[4] Valvular heart disease commonly found in clinical practice may hide undetected amyloidosis, as observed in autopsy series of patients with severe aortic stenosis undergoing TAVI (mild to severe myocardial and valvular involvement, in 33% of cases)[5] and in patients with severe calcific aortic stenosis subjected to traditional aortic valve replacement, evaluated by myocardial scintigraphy (ATTR in 16% of cases).[6] It is currently estimated that ~5% of hypertrophic cardiomyopathies actually are unrecognized amyloidosis.[7] Moreover, current epidemiological studies are burdened by a significant bias: mortality is, in fact, higher in the vicinity of the reference centres and lower in the regions with the highest density of Afro-American population[8] where it is known that the disease is more frequent because it is often caused by genetic mutations (the Val122Ile mutation affects almost exclusively Afro-Caribbean populations with a prevalence of 3–4%).[2] For these reasons, it is considered by many experts that the ATTR will probably become the most frequent form of CA in the world in the coming years.[2]

The clinical suspicion: the basis of an early diagnosis

The heterogeneity of clinical presentation, the main cause of the high diagnostic difficulty, follows the ability of the amyloid to be deposited virtually in any tissue, without a clear correlation between the deposit site and the specific precursor. Although crucial for the prognosis of patients, cardiac involvement is inscribed in a framework of diffuse multi-organ (heart, kidneys, liver, gastrointestinal tract, lungs, and soft tissues) disease with a clinical manifestation rich in extra-cardiac objective findings, especially in the early stages of natural history, which bring patients to the attention of various non-cardiology specialists, called upon to confirm the clinical suspicion and activate the multidisciplinary diagnostic process, also at cardiac level.

Of all, the carpal tunnel syndrome deserves special mention, especially if bilateral. In male subjects, this is highly suggestive of ATTR (up to 50% of subjects) and in the studies, it seems to precede the cardiac involvement of 5–7 years.[9] Capillary fragility, alteration of the coagulation cascade from hepatic dysfunction, autonomic neuropathy, lymphadenopathy, and progressive renal dysfunction may be variably present and constitute the phenotype of clinical presentation of patients.

Although pathognomonic and subtype-specific signs and symptoms do not exist, the AL form is characterized by soft tissue infiltration (e.g. macroglossia) and almost constant renal involvement, while the ATTR form causes more subtle manifestations, such as peripheral neuropathies and alterations of the nervous system with neurodegenerative evolution, sometimes with occurrence within a family.[9] The main clinical manifestations that can guide the suspected diagnosis are shown in *Table 1*.

Downloaded from https://academic.oup.com/eurheartjsupp/article/22/Supplement_E/E142/5851037 by guest on 26 August 2021

Table 1 Clinical manifestations of ATTR and AL amyloidosis

	ATTR	AL
Heart failure	+	+
Coronary disease (often microvascular)	+	++
Atrial fibrillation/flutter	+	+
Valvular leaflets thickening	++	+
Pericardial effusion	+	+
Decreased GLS (con apical sparing)	+	+
Low-voltage QRS	+	++
AVB	+	+
Capillary friability	+	+
Coagulation abnormalities (liver dysfunction)	+	+
Hepatomegalia	++	++
Splenomegalia	+	+
Macroglossia	+	++
Periorbital purpora	−	++
Dysfonia	+	+
Renal damage	+	++
Lymphadenopathy	−	++
Bone pain	−	++
Immune deficit	−	++
Urinary incontinence	+	+
Lower bowel dysfunction	+	+
Sensory neuropathy	++ (ATTRm)	+
Motor neuropathy	+	+
Carpal tunnel syndrome	++	+

AL, immunoglobulin light chain; ATTR (m), amyloid transthyretin (mutated); ABV, atrioventricular blocks; GLS, global longitudinal strain.

Cardiac amyloidosis: need for an integrated diagnostic pathway

The heart may be affected at the level of myocardium, coronaries (more frequently in AL amyloidosis, in non-obstructive form, but in cases of microvascular obstruction it may involve episodes of angina in healthy epicardial coronary vessels), endocardium (especially atrial, 'patchy' or widespread, increasing the incidence of atrial fibrillation and flutter), valves (causing valve insufficiency or stenosis), epicardium and parietal pericardium (pericardial effusion). For reasons still unknown, the deposit proceeds from the basal segments of the ventricle to the apical regions according to a constant pattern, increasing the total volume of the heart muscle up to a picture of overt ventricular hypertrophy with a concentric or predominantly septal pattern. The preferred place to store is the postero-basal inter-ventricular septum which, mimicking the echocardiographic aspect of hypertrophic cardiomyopathy, introduces an element of further complexity into the already difficult differential diagnosis. With the progression of the disease, the deposit becomes more widespread up to the involvement of the cardiac apex.[5]

Signs and symptoms related to cardiac involvement, although indicators of an often advanced stage of disease, may represent the clinical manifestation of onset: the most frequent presentation is heart failure in the presence of hypertrophic ventricles (at least in the initial phase), with diastolic dysfunction of varying degrees and signs of systemic venous congestion (jugular turgor, hepatomegaly, and bilateral oedema). Other symptoms include palpitations sustained by hyperkinetic arrhythmias (e.g. flutter or atrial fibrillation), chest pain due to involvement of the coronary microcirculation, also with typical features for angina, and recurrent syncope due to orthostatic hypotension due to autonomic dysfunction or infiltration of the sinus node. As in many fields of medicine, the diagnosis of CA is a fine and structured process according to the outcome of first and second level exams, such as electrocardiogram, laboratory tests and echocardiography, analysed in a suggestive clinical context. *Table 2* contains some elements of strong clinical suspicion from which a diagnostic procedure aimed at confirming the presence of CA must begin.

The critical reading of the electrocardiogram is often widely underestimated, but it plays an important role in the diagnosis of CA. Cardio-myocytes in contact with amyloid loose progressively their function both mechanically and electrically: the low peripheral and precordial voltages, which are more frequent in the AL subtype than the ATR, are the expression of this electrical isolation (60% vs. 20%).[10] The contrast with ventricular hypertrophy at echocardiography is the most significant suspect element for the pathology.[11]

Commonly detectable alterations are the 'pseudo-infarct' pattern (70% of cases) characterized by poor progression of the R wave or by QS[10] complexes, atrioventricular blocks (generally I degree), non-specific intraventricular conduction delays, supraventricular tachycardia (atrial fibrillation or flutter) and complex ventricular arrhythmias (<25% of cases). Similar to low voltages, the association of atrioventricular blocks in hypertrophic ventricles must raise the suspicion of CA.[2]

From the laboratory point of view, the confirmation of CA in the AL form passes through the search for the monoclonal component, in serum and urine, and the identification of the plasma cell clone producing light chains. The first-level exams—serum-protein electrophoresis, beta2 microglobulin, and indexes of renal function—are negative in 30–40% of patients: in this case, the serum and urinary immunofixation in combination with the dosage of free plasma light chains allow to detect the activity of the medullary clone with a sensitivity close to 99%.[2] The alteration of the normal kappa-lambda ratio (normal values between 0.26 and 1.65) reflects the unbalanced production of a specific light chain 12, often hypofunctional. However, an altered relationship is not a sufficient parameter for diagnosis, as it can occur in 5% of the population > 65 years as MGUS,[13] and can sometimes coexist with a TTR CA. These patients may receive an erroneous diagnosis of AL form (up to 10% of cases).[12]

The direct toxicity of pre-amyloid proteins on cardiomyocytes involves particularly high and out-of-proportion serum levels of BNP and NT-proBNP compared to the degree of haemodynamic decompensation of patients and a plateau troponin release. However, there is no accurate first-level laboratory test to identify the ATTR form and the circulating transthyretin dosage is not reliable for diagnosis.[2]

As a result of the high accessibility to instrumental examinations, typical of the current era of 'fast and

Downloaded from https://academic.oup.com/eurheartjsupp/article/22/Supplement_E/E142/5851037 by guest on 26 August 2021

Table 2 'Red Flags' in the cardiac amyloidosis

The diagnosis of AC must always start from a high degree of clinical suspicion
In patients with heart failure with conserved systolic function and hypertrophy of the walls, the diagnosis of AC must be considered
Patients with suspected HCM should always be critically evaluated to search for clinical-instrumental elements that can direct them towards an accumulation of heart disease (VP, ABV, etc.)
Elderly patients with IVS in the absence of hypertension or aortic valve stenosis should be considered for AC
Low QRS voltages to the ECG in the presence of IVS are suspected for AC
AC from TTR and MGUS can coexist: an AC in the presence of monoclonal gammopathy is not necessarily AL
GLS in AC is often significantly reduced (typically with apical savings), even in the presence of normal LVEF
Magnetic resonance in both T1 signalling and extracellular oedema in IVS patients are very suggestive of AC. The distribution of the LGE is heterogeneous and the subendocardial distribution is not the only possible pattern
The history of bilateral carpal tunnel syndrome in a man with IVS is very suggestive of AC ATTRwt

AC, cardiac amyloidosis; AL, immunoglobulin light chain; ATTR, amyloid transthyretin; ATTRwt, wild-type amyloid transthyretin; ABV, atrioventricular blocks; GLS, global longitudinal strain; HCM, hypertrophic cardiomyopathy; IVS, left ventricular hypertrophy; LGE, late gadolinium enhancement; LVEF, ejection fraction of the left ventricle; MGUS, monoclonal gammopathy of uncertain significance; VP, pericardial effusion.

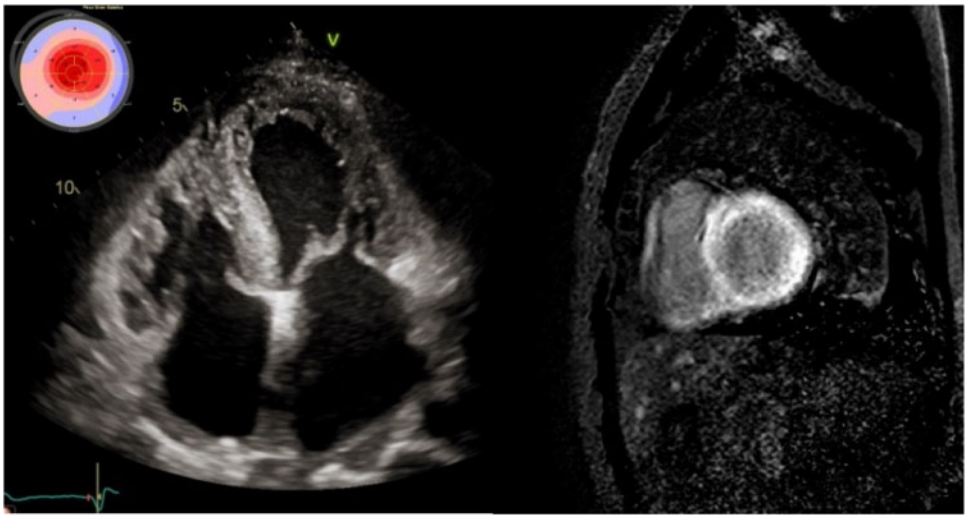

Figure 2 Left: echocardiogram of a patient suffering from AL amyloidotic cardiomyopathy, apical four chambers projection. In the upper left corner, 'bull's eye' representation of the longitudinal strain with the typical 'apical sparing' aspect. Right: cardiac magnetic resonance imaging of a patient with transthyretin amyloidotic cardiomyopathy (post-contrastographic sequence and basal short-axis section) with the typical appearance of diffuse late gadolinium subendocardial enhancement.

high-tech' medicine, echocardiography appears to be a rapid and concrete answer to clinical questions, but its diagnostic value is proportional to the critical reading of findings. In fact, there are no pathognomonic echocardiographic criteria of CA. The alterations are very suggestive in advanced disease but can be faded in the initial stages, especially in the presence of normal parameters of systolic function. The widespread thickening of the cardiac muscle, with a biventricular imprint, generally symmetrical and with an altered echogenicity pattern of the 'granular sparkling' type, characterizes the echocardiographic picture of the amyloidotic heart and constitutes an element of high suspicion (*Figure 2*). The TTR form has more increased wall thicknesses than the AL form,[14] but this criterion does not help to morphologically differentiate the two subtypes. This 'false hypertrophy' of amyloidotic infiltration may in rare cases have a predominantly septal expression, mimicking hypertensive or hypertrophic heart disease.[13] Diastolic dysfunction is usually the most precociously detectable alteration in echocardiography and involves both ventricles, it has a progressive character marked by the altered ventricular relaxation at high-grade restrictive dysfunction in the advanced stages of the disease (21–88% of the cases of CA).[15] The increase in filling pressures in a right ventricle with diastolic dysfunction also leads to changes in blood flow in the vena cava and suprahepatic veins system.

An early sign of cardiac involvement is represented by the reduction of the district myocardial velocities detected with the Tissue Doppler study in patients with preserved ejection fraction and the increase of the E/E ratio, already at an early stage, may guide the difficult differential diagnosis with constrictive pericarditis.

Recent innovations in the field of myocardial deformation imaging have made it possible to measure performance and the mechanics of ventricular contraction with

Downloaded from https://academic.oup.com/eurheartjsupp/article/22/Supplement_E/E142/5851037 by guest on 26 August 2021

strain analysis. Specifically, the longitudinal strain has district variations, being more compromised in the basal segments than in the other ventricular regions. Proceeding from the basal segments to the apical, the analysis of cardiac deformation detects a 'strain gradient' characteristic of this pathology that reflects in functional terms the two-dimensional observation of the normal apical kinetics ('apical sparing', *Figure 2*).[16]

The mild pericardial effusion (up to 50% of cases) is a frequent finding, secondary to the infiltration of amyloid, which also affects the atrioventricular valves (often insufficient) and the interatrial septum.[15] The bi-atrial dilatation is also characteristic, with the possible presence of endocavitary thrombosis, also in sinus rhythm, as a consequence of a less-than-effective atrial contraction.

In selected patients with non-severely impaired renal function, cardiac magnetic resonance imaging (CMR) is a highly informative test for the clinician in the differential diagnosis, where a monoclonal component is identifiable in the absence of clear elements of cardiac involvement at first investigations level. Although there is no pathognomonic picture at CMR, according to many experts a late enhancement of diffuse subendocardial gadolinium is highly suggestive of CA[2] (*Figure 2*). Multiparametric evaluation of extracellular volume, late impregnation of gadolinium and T1 mapping allows us to estimate the amyloidotic burden, the rate of cardiac oedema and the adaptations of cardiomyocytes, representing a useful tool in patient follow-up.[2]

Confirmation of suspicion: myocardial scintigraphy with bone tracer

Although the diagnostic gold standard of amyloidosis has always been histological examination by endomyocardial or extra-cardiac biopsy (umbilical, rectal, or salivary glands), methods of nuclear medicine have progressively challenged this paradigm. It has been known for decades that the bone tracers have a marked affinity for the myocardial deposits of transthyretin and, to a lesser extent, for the deposits of light chains of immunoglobulins or other forms of amyloid (*Figure 1*, lower right panel), and validation studies against histology have unequivocally demonstrated high sensitivity and diagnostic specificity of scintigraphy for TTR2 amyloidotic cardiomyopathy. The combination of this test with the search for serum monoclonal component (as discussed above) allows, in the patient with high clinical suspicion and compatible first-level imaging, to confirm or exclude with very high diagnostic accuracy an amyloidotic cardiomyopathy from TTR or AL, restricting very much the role of the biopsy, which on this basis, is reserved for the few doubtful cases. On these bases, some diagnostic flowchart models have been proposed in the literature.[2]

Therapeutic perspectives

With regard to amyloidosis, especially in the ATTR form, so far orphan of therapies able to impact on prognosis, there is currently great fervour for the development of new drugs: molecules able to stabilize transthyretin to prevent the loss of the tetrameric structure (passage key of amyloidogenesis), siRNA and oligonucleotides silencing the protein's hepatic production, molecules capable of degrading and removing already formed deposits. Among these drugs, tafamidis, belonging to the category of TTR stabilizers, is supported by recent solid efficacy data in terms of mortality and hospitalization, in phase three trials.[17] These data definitively underline the need for an early diagnosis of CA, given the possibility, in the coming years, of being able to change its natural history.

Conclusions

AC is a heterogeneous and often misunderstood disease, able to mimic different pathological conditions. Despite the new discoveries in the pharmacological field, a late diagnosis significantly affects the prognosis of the patients and the possibility of undertaking disease-modifying therapies (e.g. liver transplantation in ATTR or bone marrow transplantation in AL) capable of healing or slowing the progression of the disease. Knowing the complex picture of signs and symptoms related to amyloidosis makes it possible to ignite the clinical suspicion and consequently start the appropriate diagnostic and therapeutic procedure.

Conflict of interest: none declared.

References

1. Merlini G, Bellotti V. Molecular mechanisms of amyloidosis. *N Engl J Med* 2003;**349**:583–596.
2. Maurer MS, Elliott P, Comenzo R, Semigran M, Rapezzi C. Addressing common questions encountered in the diagnosis and management of cardiac amyloidosis. *Circulation* 2017;**135**:1357–1377.
3. Lousada I, Comenzo RL, Landau H, Guthrie S, Merlini G. Light chain amyloidosis: patient experience survey from the amyloidosis research consortium. *Adv Ther* 2015;**32**:920–928.
4. Mohammed SF, Mirzoyev SA, Edwards WD, Dogan A, Grogan DR, Dunlay SM, Roger VL, Gertz MA, Dispenzieri A, Zeldenrust SR, Redfield MM. Left ventricular amyloid deposition in patients with heart failure and preserved ejection fraction. *JACC Hear Fail* 2014;**2**:113–122.
5. Maleszewski JJ. Cardiac amyloidosis: pathology, nomenclature, and typing. *Cardiovasc Pathol* 2015;**24**:343–350.
6. Castaño A, Narotsky DL, Hamid N, Khalique OK, Morgenstern R, DeLuca A, Rubin J, Chiuzan C, Nazif T, Vahl T, George I, Kodali S, Leon MB, Hahn R, Bokhari S, Maurer MS. Unveiling transthyretin cardiac amyloidosis and its predictors among elderly patients with severe aortic stenosis undergoing transcatheter aortic valve replacement. *Eur Heart J* 2017;**38**:2879–2887.
7. Damy T, Costes B, Hagège AA, Donal E, Eicher J-C, Slama M, Guellich A, Rappeneau S, Gueffet J-P, Logeart D, Planté-Bordeneuve V, Bouvaist H, Huttin O, Mulak G, Dubois-Randé J-L, Goossens M, Canoui-Poitrine F, Buxbaum JN. Prevalence and clinical phenotype of hereditary transthyretin amyloid cardiomyopathy in patients with increased left ventricular wall thickness. *Eur Heart J* 2016;**37**:1826–1834.
8. Alexander KM, Orav J, Singh A, Jacob SA, Menon A, Padera RF, Kijewski MF, Liao R, Di Carli MF, Laubach JP, Falk RH, Dorbala S. Geographic disparities in reported US amyloidosis mortality from 1979 to 2015. *JAMA Cardiol* 2018;**3**:865.
9. Falk RH. Diagnosis and management of the cardiac amyloidoses. *Circulation* 2005;**112**:2047–2060.
10. Cyrille NB, Goldsmith J, Alvarez J, Maurer MS. Prevalence and prognostic significance of low QRS voltage among the three main types of cardiac amyloidosis. *Am J Cardiol* 2014;**114**:1089–1093.

Downloaded from https://academic.oup.com/eurheartjsupp/article/22/Supplement_E/E142/5851037 by guest on 26 August 2021

11. Quarta CC, Solomon SD, Uraizee I, Kruger J, Longhi S, Ferlito M, Gagliardi C, Milandri A, Rapezzi C, Falk RH. Left ventricular structure and function in transthyretin-related versus light-chain cardiac amyloidosis. *Circulation* 2014;**129**:1840–1849.
12. Dispenzieri A, Katzmann JA, Kyle RA, Larson DR, Melton LJ, Colby CL, Therneau TM, Clark R, Kumar SK, Bradwell A, Fonseca R, Jelinek DF, Rajkumar SV. Prevalence and risk of progression of light-chain monoclonal gammopathy of undetermined significance: a retrospective population-based cohort study. *Lancet* 2010;**375**:1721–1728.
13. Finocchiaro G, Pinamonti B, Merlo M, Giannini F, Barbati G, Pivetta A, Santarossa E, Doimo S, DePellegrin A, Bussani R, Sinagra G. Focus on cardiac amyloidosis. *J Cardiovasc Med* 2013;**14**:281–288.
14. Dungu JN, Valencia O, Pinney JH, Gibbs SDJ, Rowczenio D, Gilbertson JA, Lachmann HJ, Wechalekar A, Gillmore JD, Whelan CJ, Hawkins PN, Anderson LJ. CMR-based differentiation of AL and ATTR cardiac amyloidosis. *JACC Cardiovasc Imaging* 2014;**7**:133–142.
15. Klein AL, Hatle LK, Burstow DJ, Seward JB, Kyle RA, Bailey KR, Luscher TF, Gertz MA, Jamil Tajik A. Doppler characterization of left ventricular diastolic function in cardiac amyloidosis. *J Am Coll Cardiol* 1989;**13**:1017–1026.
16. Ternacle J, Bodez D, Guellich A, Audureau E, Rappeneau S, Lim P, Radu C, Guendouz S, Couetil J-P, Benhaiem N, Hittinger L, Dubois-Randé J-L, Plante-Bordeneuve V, Mohty D, Deux J-F, Damy T. Causes and consequences of longitudinal LV dysfunction assessed by 2D strain echocardiography in cardiac amyloidosis. *JACC Cardiovasc Imaging* 2016;**9**:126–138.
17. Maurer MS, Schwartz JH, Gundapaneni B, Elliott PM, Merlini G, Waddington-Cruz M, Kristen AV, Grogan M, Witteles R, Damy T, Drachman BM, Shah SJ, Hanna M, Judge DP, Barsdorf AI, Huber P, Patterson TA, Riley S, Schumacher J, Stewart M, Sultan MB, Rapezzi C. Tafamidis treatment for patients with transthyretin amyloid cardiomyopathy. *N Engl J Med* 2018;**379**:1007–1016.

Downloaded from https://academic.oup.com/eurheartjsupp/article/22/Supplement_E/E142/5851037 by guest on 26 August 2021